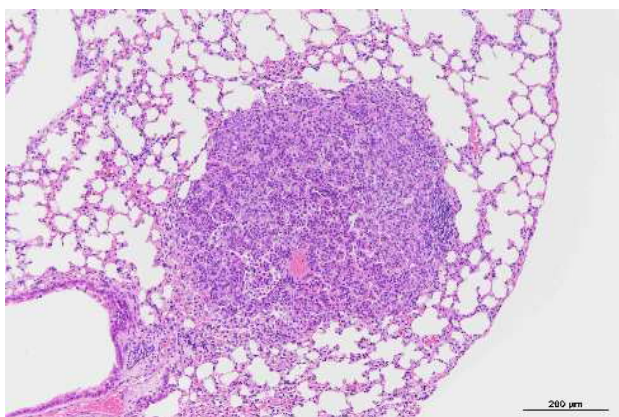


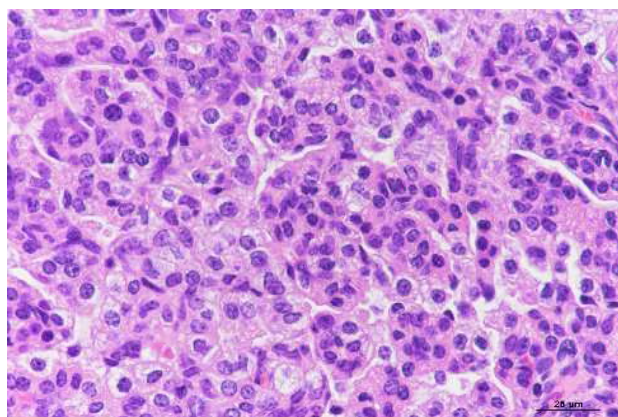
アリルアルコールの rasH2 マウスを用いた  
吸入による中期発がん性試験報告書

試験番号：0926

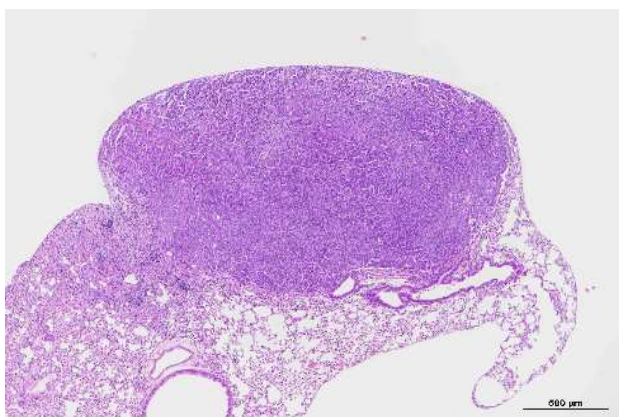
# PHOTOGRAPHS



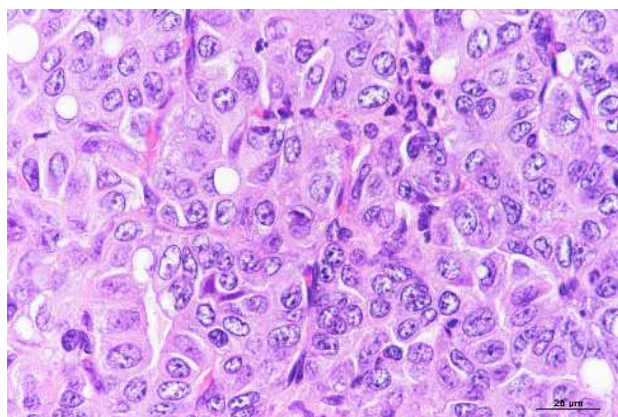
Photograph 1  
Lung: Bronchiolar-alveolar adenoma  
Male, 0.5 ppm, Animal No. 0926-1207 (H &E)



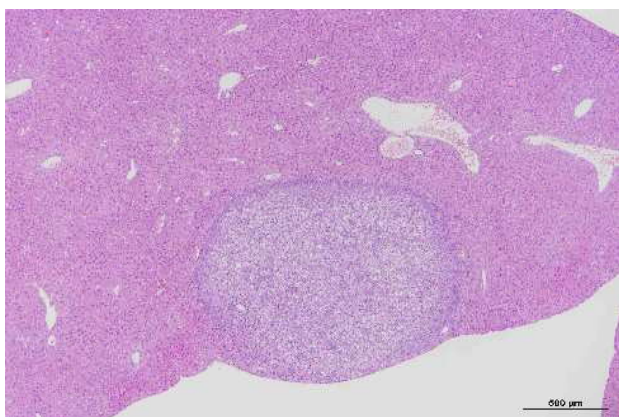
Photograph 2  
High magnification of Photograph 1



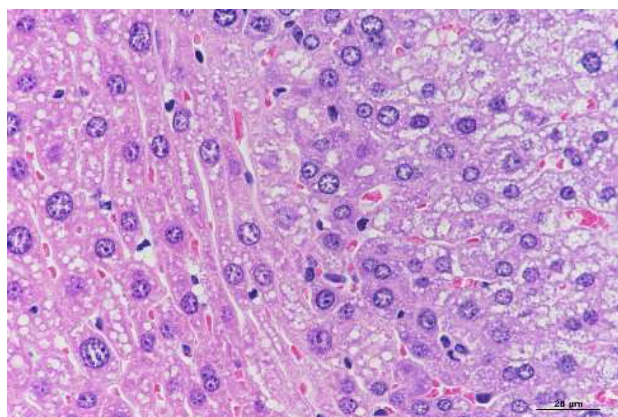
Photograph 3  
Lung: Bronchiolar-alveolar carcinoma  
Male, 0.5 ppm, Animal No. 0926-1213 (H &E)



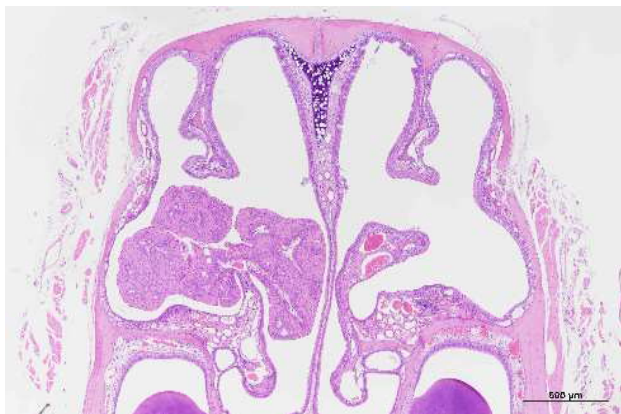
Photograph 4  
High magnification of Photograph 3



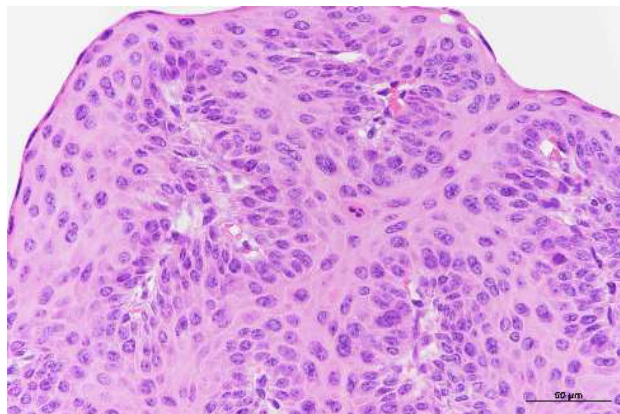
Photograph 5  
Liver: Hepatocellular adenoma  
Male, 0.5 ppm, Animal No. 0926-1220 (H &E)



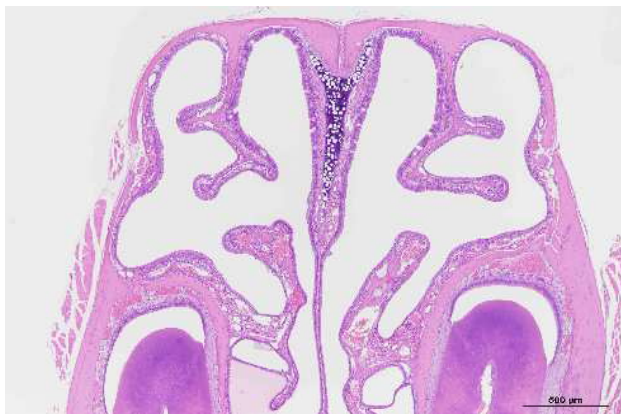Photograph 6  
High magnification of Photograph 5



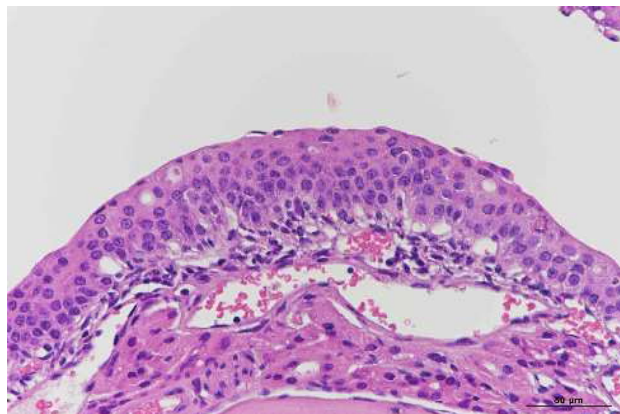
Photograph 7  
Nasal cavity: Papilloma  
Female, 1.5 ppm, Animal No. 0926-2303 (H &E)



Photograph 8  
High magnification of Photograph 7



Photograph 9  
Nasal cavity: Hyperplasia, transitional cell  
Female, 1.5 ppm, Animal No. 0926-2301 (H &E)



Photograph 10  
High magnification of Photograph 9